

TRIXACARUS CAVIAE INFESTATION IN GUINEA PIGS CASE REPORT

NARCISA MEDERLE, D. INDRE

Department of Parasitology, Faculty of Veterinary Medicine Timisoara
Calea Aradului No. 119, 300645, Timisoara, Romania
E-mail: narcisa.mederle@yahoo.com

Summary

An 1 year-old guinea pig (*Cavia porcellus*) was presented for examination because of a pruritic skin condition which had commenced approximately one month after the animal had been purchased from a pet store (Moll, Timisoara). The medical exams were: anamnesis, general examination and dermatological exam. Skin scrapings were performed and revealed numerous sarcoptid mites (adults and eggs) consistent with *Trixacarus caviae*. Weekly dips with 2.5% Taktic (Amitraz) were prescribed for six treatments. After the second bath the lesions were remitted and pruritus was absent.

Key words: guinea pigs, trixacarus caviae, amitraz

There are two mites that cause skin problems in guinea pigs. *Trixacarus (Caviacoptes) caviae* is the most common mite and the most common parasite that causes scratching. *T. caviae* causes severe scratching and self-trauma. There may also be hair loss, thickening of the skin, redness, and papules. This mite usually affects the head, shoulders, back, and flanks of the guinea pig, but may spread to the entire animal. Secondary bacterial infections can occur. The itching is so severe that some animals may appear to have seizures or other abnormal behavior. Severely infected pregnant guinea pigs may abort. Some guinea pigs may carry the mite, but show no signs. Then, if they are stressed by poor nutrition, cold temperatures, or other illnesses, they may develop the disease. The mite is transmitted by direct contact, and can temporarily infest people. An infestation with *T. caviae* can be diagnosed by a veterinarian performing a skin scraping. The mites can be difficult to find, and the veterinarian may prescribe treatment solely based on the clinical signs of disease (1, 2, 3, 6, 7).

Materials and methods

This study was performed at the Parasitological Department of the Faculty of Veterinary Medicine of Timisoara. An 1 year-old male guinea pig (*Cavia porcellus*) was presented for examination because of a pruritic skin condition which had commenced approximately one month after the animal had been purchased from a pet store (Moll, Timisoara). Medical exams were: anamnesis, general examination and dermatological exam. Primary lesions were few and consisted of occasional

papules. Pruritus was intense as manifested by intense scratching, even during this period of time. The veterinarian had previously treated the animal with an antibiomatic and corticosteroid topical preparation without benefit. On examination, the trunk was the most severely affected area with generalized erythroderma, crusting, hair loss, induration and excoriations (figure 1). The dermatological exam was realized by skin scrapings. The samples were clarified in lactofenol and microscopically examined.

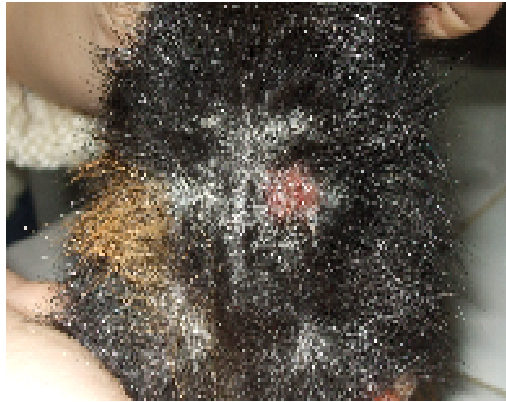

Fig. 1. Erythroderma, crusting, hair loss, induration and excoriations (original)

Results and discussions

Skin scrapings were performed and revealed numerous sarcoptid mites (adults and eggs) consistent with *Trixacarus caviae* (figure 2 and 3).

Weekly dips with 2.5% Tactic (Amitraz) were prescribed for six treatments. After the second bath the lesions were remitted and pruritus was absent. Unfortunately, we could not examine the patient in the end of therapy.

In Oxford, England (1972) as a new species of Sarcoptidae causing mange in guinea pigs (1). Since that time it has been reported in many centres in the United States. The main lesions consist of scaling, crusting, hair loss and intense pruritus (1).

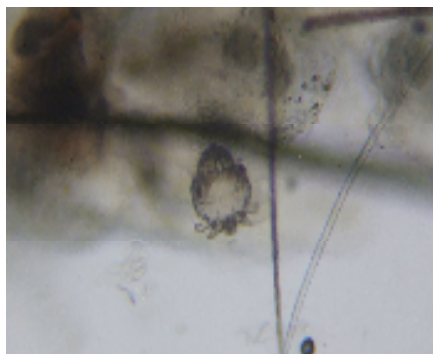


Fig. 2. *Trixacarus caviae* –adults (original)

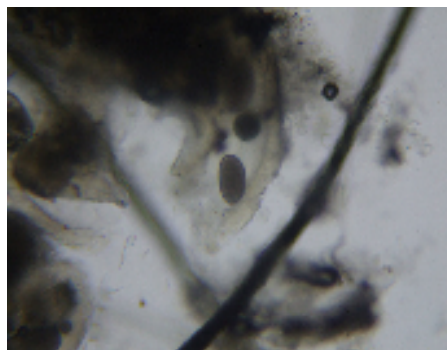


Fig. 3. *T. caviae*-eggs (original)

The diagnosis of mange in guinea pig caused by *Trixacarus caviae* is reported for the first time in Austria (1988). Mange in guinea pigs does not occur rarely. Pathological changes were observed in 5 guinea pigs kept as pets (5). Humans may be transiently affected and display a papulovesicular dermatitis. The mites appear incapable of persisting on human skin and thus treatment is usually limited to the affected animals themselves (1).

Diagnosis should be suspected from the clinical presentation and can usually be confirmed by skin scrapings. The mites are not nearly as difficult to uncover as are those of *Sarcoptes scabiei*. Biopsies usually reveal the mites in their burrows within the area of marked orthokeratotic hyperkeratosis; there is usually a mixed cell inflammatory infiltrate in the edematous superficial dermis (4).

Infected guinea pigs developed a neutrophilia, monocytosis, eosinophilia and basophilia. Despite pronounced reactive changes in the superficial lymph nodes, infected guinea pigs developed only a mild dermatitis. In contrast, home bred animals, susceptible to *T. caviae* acquired many mites and developed a severe chronic dermatitis (8)

Treatment is usually attempted with 2.5% lime sulfur which is safe and effective for animals of all ages. Other treatments reported as successful include crotamiton, 0.25% chlordane, gamma benzene hexachloride, bromocyclen baths, trichlorfon, and 10% tetraethylthiuram monosulfide at seven- ten day intervals for three to six weeks (1, 2, 6). The most common treatment is ivermectin injections every 10 days for three treatments. Animals in contact with the infested animal should be treated, as well. The mites can survive in the environment, so it is recommended that the housing be cleaned and then soaked in a lime sulfur solution at a dilution of 1:40 (one part lime sulfur to 40 parts water). Dry everything thoroughly before placing the guinea pig back into his housing (1, 3, 6).

Conclusions

An 1 year-old male guinea pig (*Cavia porcellus*) who presented intense scratching, generalized erythroderma, crusting, hair loss, induration and excoriations was diagnosed with *Trixacarus caviae*.

References

1. **Ackerman, L.**, *Trixacarus caviae* Infestation in a Guinea Pig, *Can Vet J.*, 1987, 28, 9, 613.
2. **Baker, D.G.**, *Natural pathogens of laboratory animals*, ASM Press, 2003.
3. **Beck, Wieland, Buck. W., Pantchev, F.**, Nikola-Mange due to *T. caviae* infestation, *Lab Anim*, 2007, 36, 10, 17.
4. **Fuentealba, Carmen, Hanna, P.**, Mange induced by *T. caviae* in a guinea pig, 1996, *Can. Vet. J.*, 37, 12, 749.
5. **Hinaidy, H.K., Loupal, G.**, Establishment of mange caused by *Trixacarus caviae* in guinea pigs in Austria *Tierarztl Prax*, 1988, 16, 1, 936.
6. **Holly, N.**, Common Skin Parasites that Cause Scratching in Guinea Pigs: Signs, Diagnosis, and Treatment, *Can Vet J.*, 1997, 8, 4, 302.7
7. **McDonald, S.E., Lavoipierre, M.M.**, *Trixacarus caviae* infestation in two guinea pigs, *Lab Anim Sci*, 1980, 30, 1, 67.
8. **Rothwell, T.L., Pope, S.E., Rajczyk, Z.K., Collins, G.H.**, Haematological and pathological responses to experimental *Trixacarus caviae* infection in guinea pigs., *J. Comp.Pathol*, 1991, 104, 2, 179.