

ECHOCARDIOGRAPHICAL ASPECTS IN CARNIVOROUS CARDIOPATHIES

F. SIMIZ, T. MOT, M. CRISTESCU, V. CIULAN, D. MORAR

Faculty of Veterinary Medicine Timisoara

Summary

Investigations have been performed on two different-breed dogs, with ages of 4 and 10 years old, and on one 4 month old Birman cat.

The echocardiographical examination, in the module B, reveals the presence of cavity liquids, lesions of cardiac hypertrophy, and within the module M – a deficiency in the enclosure of the mitral orifice, with interventricular septal thickening and left atrium-ventricular dilation (mitral-insufficiency dog). We have also noticed a thickening of the papillary muscles and of the interventricular wall (cat with concentric ventricular hypertrophy).

As complementary investigation procedure, the echocardiography represents a non-invasive and non-painful method.

Key words: dog, cat, cardiomyopathy, echocardiography

Nowadays cardiomyopathy represents one of the most frequent pets diseases.(1, 3,5).Unlike other investigation procedures, echocardiography is very often used because it is noninvasive, painless and it offers the investigator a lot of data about the heart dynamic activity and it allows a very precise cardiomyopathic diagnosis. (1, 2, 4)

Due to an artificial and sedentary way of life, or to overfeeding the cardiac pathology is encountered at younger and younger animals. It is sometimes hidden by some other diseases and that is why we use not only Rx and ECG, but also a more recent way of cardiological investigation, namely echocardiography.

Materials and methods

The experiment has been conducted on two dogs and a cat.

The following means have been used during the experiment:

- a special echography table/desk with a cut out area in order to facilitate the access of the probe to the heart projection area while the animal is lying in decubitus on its right side;.
- Echograph 4 D generation, IXOS vet;
- Echographic convex probe of 5 and 7.5 MHz;

The following methods have been used during the experiment: semeiological classical methods (anamnesis/case history, observation, palpation, and auscultation) and especially echographical examination.

In order to obtain the correct image the animals were lying in decubitus on the right side, the probe was placed on the heart projection area on the right side, ribs 3-6.

The image is obtained by placing the probe under the table as by this method we can obtain the best images and the heart is leaning against the chest, avoiding lung interference.

The animal can be examined while standing on its four legs if it does not accept the position mentioned above due to discomfort or dyspnea.

Results and discussions

The first case (Fig. 1) a 10 year old female Métis dog weighing 40 kg had intrathoracic metastases which have been identified during the radiological examination. The following clinical diagnoses has been established: dyspnea, cyanosis of the mucous membranes, prolonged decubitus, extended abdomen, "wave sensation " during the palpation, filiform pulse, low-intensity heart sound has been identified during the auscultation.

The abdominal and chest echography revealed hepatic megaly, liquid in the abdominal and thoracic cavity and fibrous deposits.

Some radio-opaque structures disseminated in the pulmonary parenchyma have been identified during the radiological examination.

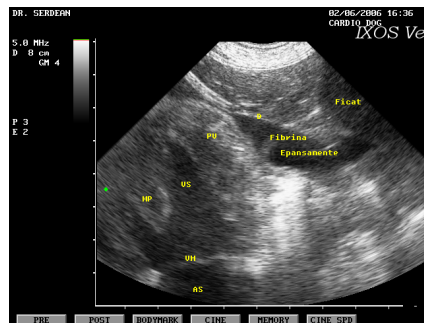


Fig 1 Cardiac hypertrophy

The second case (Fig. 2) a 10 year old female Alsatian dog weighing 28 kg had the following clinical diagnoses: dyspnea, easily congested mucous membranes, nocturnal coughing, dyspeptic syndrome, extended, increased TRC, filiform pulse, cardiac insufficiency gasp.

During the ECG we identified a slightly expanded P in D II, wide QRS complex in D II and D III and a coronary ischemia ST (segment changes)

The echography revealed an incomplete closure of the mitral valve which causes/leads to a blood flowing backward to the left ventricle.

Thus a high diastolic pressure appeared and led to a left ventricular dilatation subsequently to the mitral insufficiency.

The increased left ventricular pressure increased the pulmonary venous pressure.

The second case is a 10 years old female German Sheperd with 28 kilo weight.

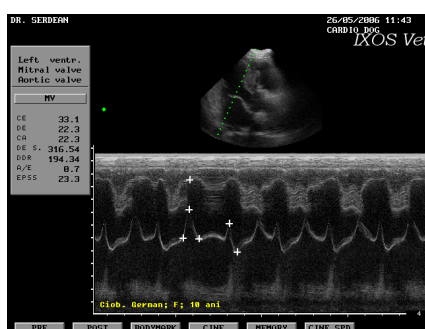


Fig 2 Echography M module
Left AV expansion/ Mitral insufficiency/ Increased ejection fraction

The third case (fig. 3) is a 4 year old male cat having the following symptoms: effort intolerance, coughing, systolic insufficiency gasp, cyanosis.

The echography revealed a thickened interventricular septum (6 mm), unexpanded left ventricle.

The diagnosis is concentric ventricular hypertrophy which led to a decreased ventricular volume.

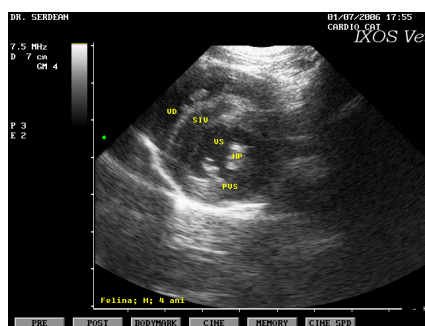


Fig. 3 Concentric ventricular hypertrophy

Conclusions

The echography (B module) revealed the presence of liquid inside the chest, pleura and the pericardial sack, cardiac hypertrophy lesions (thickened divider wall and interventricular septum) at the dog with intra thoracic metastases.

In the second case of the mitral insufficiency the echography (M module) revealed an incomplete closure of the mitral valve which led to a left AV expansion.

The concentric ventricular hypertrophy identified by the echography (B module) is made by the thickened papillary muscles and the thickened interventricular divider wall.

The echography is a modern, accurate noninvasive and painless method, being at the same time a complementary investigation procedure for the carnivorous cardiovascular pathology.

References

1. **Brăslașu, C. M., Elena Daniela Brăslașu, Irinel Georgeta Verman, Săvulescu Fiedler, Ilinca Mihaela-** Cardiologie veterinară, Diagnosticul bolilor cardiovasculare la animale, Ed. Artprint, București, 2004.
2. **Codreanu, M. D., A. Diaconescu-** Diagnosticul ecografic la animalele de companie, Ed. Coral Sanivet, București, 2003.
3. **James, G. C.,-** Textbook of Vet. Physiology, W. B. Saunders Company, SUA, 2002.
4. **Pikula, J., J., Pikulova, H., Bandouchova, P. N., Kohout, K., Tichy, F., Tremi-** Subaortic stenosis and mitral dysplasia in three Black russian terrier puppies, 2005, Vet. Med- Czech 50, (7), 321-326.
5. **Tilley, P. L., Goodwin, J. K.-** Manual of Canine and Feline Cardiology, W. B. Saunders Company, SUA, 2001.